

CAUSELESS HAPPINESS ORGANISATION-REGISTRATION FORM

SPONERSHIP FORM FOR FINANCIAL ASSISTANCE FOR MEDICAL TREATMENT

PATIENT REG NO : CHO/585/

DATE : 03/10/2024

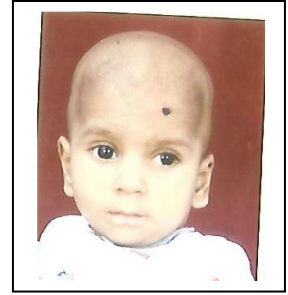BENEFICIARY DEMOGRAPHY

PATIENT'S NAME : SATYAM VERMA

AGE: 1 YEAR

RELIGION : HINDU

GENDER : MALE ☐ FEMALE ☐ TRANSGENDER ☐



PATIENT'S FAMILY DETAIL (IN MIN 30 WORDS)

Master Satyam is suffering with EYE CANCER(Retinoblastoma) and his treatment is going on AIIMS Hospital. Satyam's father was autorikshaw driver but currently unemployed due to his child's medical issue and hardly earns bread for his family. They are in very miserable situation currently, kindly help child for his chemotherapy and surgery treatment.

GUARDIAN 'S DETAIL :

FATHER'S NAME: Mr.Vishnu Verma

MOTHER'S NAME : Mrs.Rati Verma

OCCUPATION: Autorikshaw Driver

OCCUPATION : Housewife

SIBLING : BROTHER ☐ SISTER ☐ TRANSGENDER ☐

FAMILY INCOME: NA

TREATMENT DETAILS:

PATIENT SUFFERING FROM :Eye Cancer (Retinoblastoma).

TREATMENT PRESCRIBED : CHEMOTHERAPY AND SURGERY.

APPROXIMATE EXPENSE FOR WHICH FINANCIAL ASSISTANCE REQUIRED:4,00,000-5,00,000/-.

TREATMENT IS DONE AT :Aiims Hospital, New Delhi.

DECLARATION:

I HEREBY DECLARE THAT THE INFORMATION GIVEN ABOVE IS TRUE AND TO THE BEST OF MY KNOWLEDGE.I AM NOT IN THE FINANCIAL POSTION TO ARRANGE FUNDS REQUIRED FOR THE TREATMENT OF MY CHILD.I AM FULLY AWARE OF THE FACT THE ORGANISATION WILL BE RAISING FUND FOR THE TREATMENT OF MY CHILD AND I HAVE NO OBJECTION WITH IT.

(SIGN OF THE FATHER/GUARDIAN)



सत्यमेव जयते

सं. 1
No. 1

उत्तर प्रदेश सरकार
GOVERNMENT OF UTTAR PRADESH
चिकित्सा एवं स्वास्थ्य विभाग
DEPARTMENT OF MEDICAL AND HEALTH
जिला कंबाई अस्पताल गाजियाबाद
DISTRICT COMBINED HOSPITAL GHAZIABAD

प्रपत्र-5
FORM-5

जन्म प्रमाण-पत्र
BIRTH CERTIFICATE

(जन्म मृत्यु रजिस्ट्रीकरण अधिनियम, 1969 की धारा 12-17 तथा उत्तर प्रदेश जन्म मृत्यु रजिस्ट्रीकरण नियम, 2002 के नियम 8-13 के अंतर्गत जारी किया गया)
(ISSUED UNDER SECTION 12-17 OF THE REGISTRATION OF BIRTHS & DEATHS ACT, 1969 AND RULE 8-13 OF THE UTTAR PRADESH REGISTRATION OF BIRTHS & DEATHS RULES, 2002)

यह प्रमाणित किया जाता है निम्नलिखित सूचना जन्म के मूल अभिलेख से ली गई है जो कि जिला कंबाई अस्पताल गाजियाबाद तहसील गाजियाबाद जिला गाजियाबाद राज्य सघ प्रदेश उत्तर प्रदेश भारत के रजिस्टर में उल्लिखित है।

THIS IS TO CERTIFY THAT THE FOLLOWING INFORMATION HAS BEEN TAKEN FROM THE ORIGINAL RECORD OF BIRTH WHICH IS THE REGISTER FOR OF DISTRICT COMBINED HOSPITAL GHAZIABAD OF TAHSIL BLOCK GHAZIABAD OF DISTRICT GHAZIABAD OF STATE UNION TERRITORY UTTAR PRADESH INDIA.

नाम NAME: SAYAM

लिंग SEX: MALE

जन्म तिथि DATE OF BIRTH:

02-10-2023

TWO-ONE OCTOBER-TWO THOUSAND TWENTY THREE

जन्म स्थान PLACE OF BIRTH:

DISTRICT COMBINED HOSPITAL GHAZIABAD

माता का नाम NAME OF MOTHER:

RAH

पिता का नाम NAME OF FATHER:

VISHNU

आधार नंबर MOTHER'S AADHAAR NO.

आधार नंबर FATHER'S AADHAAR NO.

बच्चे के जन्म के समय माता-पिता का पता ADDRESS OF PARENTS AT THE TIME OF BIRTH OF THE CHILD

POOJA COLONY LONI GHAZIABAD UTTAR PRADESH 201102

माता-पिता के स्थायी पता PERMANENT ADDRESS OF PARENTS

POOJA COLONY LONI GHAZIABAD UTTAR PRADESH 201102

पंजीकरण संख्या REGISTRATION NUMBER:

B-2024-9-90347-006753

पंजीकरण तारीख DATE OF REGISTRATION

07-02-2024

टिप्पणी REMARKS (IF ANY):

जारी करने की तिथि DATE OF ISSUE:

28-05-24 11:30:34

जारी करने वाला प्राधिकारी ISSUING AUTHORITY:

रजिस्ट्रार (जन्म एवं मृत्यु)

REGISTRAR (BIRTH & DEATH)

जिला कंबाई चिकित्सालय गाजियाबाद

DISTRICT COMBINED HOSPITAL GHAZIABAD

UPDATED ON:

28-05-24 11:30:34



"THIS IS A COMPUTER GENERATED CERTIFICATE WHICH CONTAINS FACSIMILE SIGNATURE OF THE ISSUING AUTHORITY"

"THE GOVT OF INDIA (VIDEC) CIRCULAR NO. 112/2014-VSO(CRS) DATED 27-JULY-2015 HAS APPROVED THIS CERTIFICATE AS A VALID LEGAL DOCUMENT FOR ALL OFFICIAL PURPOSES"

"प्रत्येक जन्म एवं मृत्यु का पंजीकरण सुनिश्चित करें" / ENSURE REGISTRATION OF EVERY BIRTH AND DEATH



PATIENT'S NAME: MASTER SATYAM	AGE/SEX: 10M/M
REF. BY: AIIMS	REG. ID: 7697
TEST NAME: MRI BRAIN WITH ORBIT CONTRAST	EXAM. DATE: 29.8.2024

MRI BRAIN WITH ORBIT CONTRAST

An MRI scan done on High Gradient High Performance Philips 3.0T System using a SENSE compatible phased array Coils.

Clinical history:

Protocol:

Axial	-	T2, T2*, T1 FLAIR
Sagittal	-	T1 FLAIR
Coronal	-	T2 FLAIR
DWI		

Contrast given: Nil

IMAGING FINDINGS:

Bilateral cerebral hemispheres appear normal. No focal lesion seen.

Bilateral basal ganglia appear normal.

Both the thalami appear normal.

Ventricles and cisterns appear normal.

The corpus callosum, anterior and posterior commissures appear normal.

Pituitary gland and sella turcica are normal.

The cavernous sinuses and the internal carotid arteries are normal.

The midbrain, pons and medulla appear normal.

The superior, middle and inferior cerebellar peduncles are normal. The cerebellar vermis and the cerebellar hemispheric parenchyma reveal no significant abnormality.

The internal auditory canals and their contents are normal.

No abnormal extraaxial fluid collection.

The calvarium is normal. The orbits and their contents are normal.

Paranasal sinuses appear normal.

PATIENT'S NAME: MASTER SATYAM	AGE/SEX: 10M/M
REF. BY: AIIMS	REG. ID: 7697
TEST NAME: MRI BRAIN WITH ORBIT CONTRAST	EXAM. DATE: 29.8.2024

Orbits:

A well defined lobulated T1Wt isointense, T2Wt and STIR hypointense intraocular lesion measuring 7 x 8.5 x 7 mm is noted in the posterior aspect of left orbit arising from the retina.

Mild thickening of sclera is noted.

On post-contrast imaging lesion shows mild heterogeneous enhancement.

The uveo-scleral thickness is normal. The lens is in normal position.

The lacrimal glands appear normal.

The extra ocular muscles show normal thickness and normal spindle shape on both sides.

The optic nerves on both sides are normal. The optic nerve sheath complex thickness is normal.

The retro bulbar fat is normal on both sides.

The region of lacrimal sac and pre septal compartment appear normal.

Impression:

No significant abnormality in the neuroparenchyma.

A well defined lobulated mild heterogeneously enhancing intraocular lesion within the left lobe arising from the retina - likely retinoblastoma.

- Compared to previous MRI report size of the lesion appears to be mildly reduced.



Dr.A.Vinoth
MD (Radiodiagnosis)
Consultant Radiologist
Reg.No : TNMC 94361

ब० रो० वि० कार्ड O.P.D. Card

डा० राजेन्द्र प्रसाद नेत्र विज्ञान केन्द्र
अ० भा० आयु० सं०, नई दिल्ली - 110029

Dr. Rajendra Prasad Centre for Ophthalmic Sciences
A.I.I.M.S., New Delhi-110029

यू०एच०आई०डी० संख्या
UHID No. 107475311



नेत्र अमृत्य उपहार है
जो आप ही दे सकते हैं

अनुभाग व दिन
Section and Day VI
बुधवार व शनिवार
Wednesday & Saturday

कमरा नंबर
Cabin No.

आचार्य राधिका टंडन का एकक
Prof. Radhika Tandon's Unit

रोगी का नाम Name of the Patient <i>Satyam</i>	पुत्र/पुत्री/पत्नी S/D/W	लिंग Sex <i>M</i>	आयु Age <i>7m</i>	पता Address
दिनांक DATE	निदान DIAGNOSIS			
<i>8/8/24</i>	<p>उपचार Treatment <i>NRC done by SR-radiology</i></p> <p><i>① ON extension?</i> <i>BE intracocular mass</i> <i>① - small lens</i> <i>② - large lens</i></p> <p><i>T₁ hypointense } shows</i> <i>T₂ hypointense }</i></p> <p><i>② ON bulky - no enhancement ?</i> <i>? ON extension</i> <i>No intracranial extension</i></p>			

कृपया इस कार्ड को सुरक्षित रखें तथा अस्पताल में दिखाने के समय हर वक्त साथ लायें।

Kindly keep this Card safely and bring it on your follow-up visits.

- धूम्रपान निषेध 1. No Smoking
- कूड़ा कर्कट केवल कूड़ेदान में ही डालें 2. Use Dustbin
- थूकिये नहीं 3. No Spitting

ब. रो. वि. कार्ड O.P.D. Card

डा. राजेन्द्र प्रसाद नेत्र विज्ञान केन्द्र
अ. भा. आयु. सं., नई दिल्ली-110029

Dr. Rajendra Prasad Centre for Ophthalmic Sciences
A.I.I.M.S., New Delhi-110029



अनुभाग व दिन
Section and Day VI
बुधवार व शनिवार
Wednesday & Saturday

कमरा नंबर
Cabin No.

यू.एच.आई.डी. संख्या

UHID No.

107475311

आचार्य राधिका टंडन का एकक

Prof. Radhika Tandon's Unit

रोगी का नाम Name of the Patient	पुत्र/पुत्री/पत्नी S/D/W	लिंग Sex	आयु Age	पता Address
Satyam	Vishnu	M	11m	540, Pooja Colony, Loni Ghaziabad UP

दिनांक DATE	निदान DIAGNOSIS
	M1-9990254035

empted Category under Janani Shishu Suraksha Karyakam
O.B. 2/10/23
id upto 1/10/24
नी शिशु सुरक्षा कार्यक्रम श्रेणी के अंतर्गत छूट प्राप्त श्रेणी
नम विधि
रा

उपचार Treatment

1313/JSSK/MSWO/RPE/18/9/24 Bedcharge
रुद्रेंद्र पाल को / RUDEENDRA PAL KUMAR
चिकित्सा सहायक कल्याण अधिकारी
Medical Social Welfare Officer
अ. भा. आयु. सं. नई दिल्ली / Dr. R.P. Centre
A.I.I.M.S., New Delhi-110029

कृपया इस कार्ड को सुरक्षित रखें तथा अस्पताल में दिखाने के समय हर वक्त साथ लायें।

Kindly keep this Card safely and bring it on your follow-up visits.

- धूम्रपान निषेध 1. No Smoking
- कूड़ा कर्कट केवल कूड़ेदान में ही डालें 2. Use Dustbin
- थूकिये नहीं 3. No Spitting



अखिल भारतीय आयुर्विज्ञान संस्थान, नई दिल्ली-110029

(REVISIT)

ALL INDIA INSTITUTE OF MEDICAL SCIENCES, NEW DELHI -110029

आपातकालीन विभाग



(DEPT. OF EMERGENCY MEDICINE)

UHID No:107475311

आपातकालीन नं.(Emergency No): 2024/030/0101620

दिनांक DATE: 17/09/2024

समय TIME: 11:54:30 PM

NON-MLC

नाम NAME: MR. SATYAM

आयु AGE: 11 months 22 days

लिंग/SEX: M

S/O: VISHNU

पता ADDRESS:

मकान संख्या H.NO:

540, POOJA COLONY

माली/मुहल्ला STREET:

1 ONI GHAZIABAD

शहर प्रखंड CITY/BLOCK:

MOHE:

राज्य STATE:

UTTAR PRADESH

पिन PIN:

मोबाइल MOBILE NO:

7827597831

दूरभाष सं. PHONE NO: 7827597831

स्थान Location:

Paediatrics Emergency

द्वारा BROUGHT BY: Relative

Criticality: Red / Yellow / Green

Triage: Responsive/
Unresponsive

HR

/min

BP

mmHg RR

/min

spO2

%

Shifted to Paeds/ Main/ New Emergency

B/L RB - (B) gp. B → Regressed.
(D) gp. E.

Presenting Complaints

chemo - 14/9 and 15/9.

VCR / carbo / etoposide

Primary Assessment (ABCDE): Assessment Pentagon

<p>Airway</p> <p>Open & stable: Yes/No If No.....</p> <p>Breathing: RR 28/min</p> <p>Efforts: Normal/Poor/increased</p> <p>Auscultation:</p> <p>Air entry: Normal/poor/Differential</p> <p>Added sounds: None/Stridor/Wheeze/Crackles</p> <p>SpO2 on Room air 97%</p> <p>WT: 6.2 kg</p>	<p>Circulation</p> <p>HR 126/min</p> <p>CFT 2 secs.</p> <p>BP.....mmHg</p> <p>Peripheral pulse: Poor/Good</p> <p>Central pulse: Poor/Good</p> <p>Skin temp: Warm/cool</p> <p>Others</p> <p>C/o fever</p>	<p>Disability</p> <p>GCS awake/alert</p> <p>Pupil size 4mm/min</p> <p>Pupillary Reactions RT.</p> <p>Motor activity:</p> <p>Normal & Symmetrical/ Asymmetrical/ Posturing/Flaccidity/Seizure</p> <p>Blood Sugar.....mg/dl</p> <p>Exposure:</p> <p>Temp 99.6°F</p> <p>Colour: Normal/pallor/cyanosis/ mottled</p> <p>Any other skin lesions.....</p>
--	---	---

Diagnosis

1 efo. vomiting

1 efo loose stools (semi-solid)

No oral ulcers

C/o cough x 2 days

evening
(@ 4pm)

Comms
CBC

9582693400 mobile

CK-94290



अ० भा० आ० सं० अस्पताल / A.I.I.M.S. HOSPITAL

बहिरंग रोगी विभाग / Out Patient Department

अस्पताल के अन्दर धूम्रपान मना है / SMOKING IS PROHIBITED IN HOSPITAL PREMISES



बाल चिकित्सा विभाग

UHID:107475311

ABHA:

satyam2023 220723 010101

Dept No: 20240030012735

SATYAM

कमरा / Room

C-210

Queue /
संख्या

F46

Unit-III, Paediatric

OPR-6

नं० पंजीकृत सं० / O.P.D. Regn. No.

S/O VISHNU

0Y 11M 9D / M(पुरुष)

540, POOJA COLONY, LONI GHAZIABAD,

UTTAR PRADESH, INDIA

Ph: 7827597631

Follow Up Patient

General Rs 0

SAT बुक एपि

Reporting 18 148
04/09/2024आयु
Age

पता / Address

निदान / Diagnosis

दिनांक / Date

उपचार / Treatment

R/W in Desc clinic tone

a.
7/9/24.

T. Acyclovir 400mg Qid (for father)

Father has skin lesions on
face. (likely varicella)

Pls send father home.



CLEAN AND GREEN AIIMS / एम्स का पौष्टिक संकल्प, स्वच्छता से काया कल्प

अंगदान - जीवन का बहुमूल्य उपहार / ORGAN DONATION - A GIFT OF LIFE



Dr. Rajendra Prasad Centre For Ophthalmic Sciences
ALL INDIA INSTITUTE OF MEDICAL SCIENCES (AIIMS), New Delhi, 110029

Discharge Report
PROVISIONAL DISCHARGE CERTIFICATE

UHID : 107475311
Name: Mr. SATYAM
Age/Sex: 11 mons 26 days / Male
Ward Name: 1A
Address: 540, POOJA COLONY, LONI GHAZIABAD, UTTAR PRADESH, INDIA
Mobile No: 7827597831
Date of Admission: 18/09/2024 10:12:45 AM
Date of Discharge: 20/09/2024 02:10:00 PM

Cr No: R 037615 24
Department: R. P. Centre (Eye Centre)
Unit: Unit VI
Bed No.: 124

Drug Allergy, if any :-

ICD Code: C69
ICD Description: Malignant neoplasm of eye and adnexa

Diagnosis: RE REGRESSED MULTIOXAL GLOBULAR
LE CHEMOREDUCTED EMB

Investigation
Systemic: NO SI
Ocular: RE
VA FOLLOW LIGHT
IOP DIG N
LE
VA DOES NOT FOLLOW LIGHT
IOP DIG N

Treatment/Operative Procedure
Surgeon: CANCELLED I/V/FEVER AND URTI
Date: 20/09/2024
and low Hb 8.6 gm/dl

Condition at Discharge
Vision: SAME AS ADMISSION
Anterior Seg.: SAME AS ADMISSION
IOP: SAME AS ADMISSION
Posterior Seg.: SAME AS ADMISSION

Advice During Discharge
Oral: SYP PCM (125/5) 4ML SOS FOR FEVER
SYP MYXTRA 3ML TDS
Follow Up: T/U in Monday in OHRB clinic for new DOA with CBC report
C/S/B Peds JR

Prepared By: Dr. *Winters*
Richa

Signature Of Senior Resident

Date & Time

Adv: - Syp PCM (125/5) 4ml SOS
Syp Maxtone 3ml TDS
child need Hb of atleast 10 gm/dl
for sx procedure & GA
↓
Advised to get blood transfusion done
@ 10ml/kg for Hb optimization once fever settles

डा० राजेन्द्र प्रसाद नेत्र विज्ञान केन्द्र

For Ophthalmic Sciences

एम.आर.-

M.R. -9

DR. RAJENDRA PRASAD CENTRE FOR OPHTHALMIC SCIENCES

UHID:107475311

Date 18/09/2024 10:32:45 AM

CR No.:R 037615 24

Ward Name: 1A Bed No:

Name: MR. SAIYAM

124

Unit In-charge Dr. Radhika

Tandon

Unit-VI

Sciences, New Delhi-110029

CONSULTATION RECORD

वैवाहिक स्थिति

Marital Status

व्यवसाय

Occupation

के.पं.सं.

C.R. No.

धर्म

Religion

स्थिति

Status

Referred by Dr. SR Ophtho

Requesting Doctor

to Dr. SR PHDU

Consultant & Specialty

Findings :

Date :

Dear maam

This child is posted for LE eye for EO RB.

This child has undergone IVC on 14/9/24 + hb fever. for which ~~At Present~~ Hb was given in Ped Care facility.

At Present child has fever and cough & cold also his Hb is 8.6 gm.

Kindly evaluate child & give He have to plan encephal but child Hb is 8.6. Kindly tell if there is transfusion.

Thankyou

Diagnosis or Impression :

Recommendations:

Consultant's Sign



अ० भा० आ० सं० अस्पताल / A.I.I.M.S. HOSPITAL बहिरंग रोगी विभाग / Out Patient Department



IBITED IN HOSPITAL PREMISES

बाल चिकित्सा विभाग
UHID: 107475311

कमरा / Room

Queue /
संख्या

C218
N12

0211

OPR-6

Dept No: 202406030012735

SATYAM

SIDHSHU

07/04/2024 / मंगलवार

541 POUQUADOLONY, LONI GHADABAI

UP, AR PRADESH, INDIA

PH: 7827597821

New Patient

General Rs

SAT बुध रानि



Reporting: 08:49:46
08/08/2024

10 दि० पंजीकृत सं० / O.P.D. Regn. No.

आयु
Age

पता / Address

निदान / Diagnosis

दिनांक / Date

उपचार / Treatment

24

S-SK

LP Pabonkhor

211

2 IP meet, Near

815122

Ch:

- whitish reflex in Left Eye x 2 1/2 month -
No W/O discharge/redness/proptosis

H/O RB/ any other malignancy in family

O/C:

HR: 120/m

RR: 24/m

PP/CP: WP

Peripherals: norm.

CF: < 3 sec.

PT/ET - decay E-

PIA: soft NT
No OM

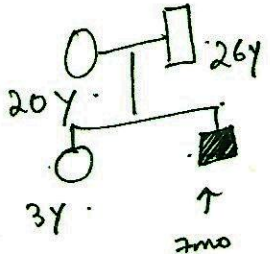
Chud:

B/LAE equal
NAD

CNS: WNL

CNS:

(N) S1, S2 heard
No murmur



CLEAN AND GREEN AIIMS / एम्स का यही संकल्प, स्वच्छता से काया कल्प

अंगदान-जीवन का बहुमूल्य उपहार / ORGAN DONATION - A GIFT OF LIFE



- IOP - 14 mmHg
- 26 mmHg.

- EVA: RE - Multifocal Group B RB.
LE - Group E RB.

(7/5/24)

- USG:
29/7/2024.

(R) - small lesion - calcification: 1 peripheral lesion (+)

(L) - large mass filling entire globe - calcification.

B/E 30 RB. | T1 ↑, T2 ↓ |

(L) ON Bulky - no enhancement
? ON extension.
No intraserial extension.

- NRC discussion:
(6/5/24)

Adv:

- Baseline MRI for staging.
[Group E v/s EORB] - RC discussion.

- CBC/RFI/UA/Viral markers - small lab

- Mantoux - 205

- 2D-echo

- Hearing assessment

- N/V in PCSC at 2PM on 9/7/24
for films in 217.

9/5/24 DIRE

Baseline MRI -

- B/L Intraocular

- no ON involvement

* appointment for genetics OPD

Sham

Post
Tuesday/Friday



UHID: 107475311
Dept No 20240058054131
Clinic No.: 2024/RB/137
SATYAM
S/O: VISHNU

7M/M

Date 15/05/2024
Retinoblastoma-Dr. SR RB
clinic UNDER UNIT VI
R-142B
Unit-VI
Room No.: 142

Address 50, POOJA COLONY, LONI GHAZIABAD, UTTAR PRADESH,
INDIA
Mobile 78:7597831

C1805241418 107475311

LH1805241012 107475311

SATYAM

B/e Retinoblastoma $\left\{ \begin{array}{l} (R) \text{ multifocal Group B} \\ (L) \text{ Group E RB} \end{array} \right.$

Received CEV (HD CEV) on 11/05/24.

% Fever x 1 day.

Cough x 5 days

loose stool x 3 days.

% E. — Afebrile

Pallor (+).

% A — eff, liver — not palpable

Quet — Cradib (+)

NVBS

HR — 110/min

RR — 30/min

17/05/24.
TLC — 4850
6.3 — 2.43L
ANC — NA

U/C — 17/0.2 U. acid — 3.2

Ca/P — 9.2/5 Na/K — 123/4.3.

TB/DB — 0.27/0.08

AST/ALT — 38/23/168.
ALP

TP/Alb — 6.3/4.1

Blood CS — awaited

ABV/S — Continue IV antibiotic.

a. Respiratory viral panel

$\left\{ \begin{array}{l} \text{Influenza} \\ \text{COVID-19} \end{array} \right.$

3. collect Blood CS

Room no 46
(18/05/24)

17/05/24

Chest X-ray — Bilateral

Infiltrates (+).

अखिल भारतीय आयुर्विज्ञान संस्थान
ALL INDIA INSTITUTE OF MEDICAL SCIENCES
 अंसारी नगर, नई दिल्ली-११००२९
ANSARI NAGAR, NEW DELHI-110029

TRANSFUSION CHART

नाम : _____ आयु _____ लिंग _____ यू.एच.आई.डी.सं. _____
 NAME : Satyan AGE : 8m SEX: M UHID No. : 107475311
 WARD : PCOPD BED NO. : _____ DIAGNOSIS : Retinoblastoma.
 PATIENT'S BLOOD GROUP : _____ UNIT CHIEF : _____

C O M P O N E N T S									Bag Group	Rh	Checked by	Started by	Given by	Stop time	REACTION
Date	Starting time	Bag No.	WB	RBC	PLT	FFP	PLSM	CRYO							
24/6	9pm	2024 B24624		✓					A	neg	Dr Navodit	N/O Monika	B T S E T		
Mid way 60x 5mg iv stat.															

W.B. = WHOLE BLOOD PLAM = PLASMA
 R.B.C. = RED BLOOD CELL CRYO = CRYOPRECIPRATE
 P.L.T. = PLATELET QTY. = QUANTITY
 FFP = FRESH FROZEN PLASMA

DATE

	DETAILS OF BLOOD REACTION, IF ANY	
	ACTION TAKEN	
	CAUSE OF BLOOD REACTION	
	OUTCOME	



अखिल भारतीय आयुर्विज्ञान संस्थान, नई दिल्ली-110029
ALL INDIA INSTITUTE OF MEDICAL SCIENCES, NEW DELHI - 110029

आपातकालीन विभाग

(REVISIT)



(DEPT. OF EMERGENCY MEDICINE)

UHID No:107475311

आपातकालीन नं.(Emergency No): 2024/030/0063401

दिनांक DATE: 24/06/2024

समय TIME: 06:47:30 PM

NON-MLC

नाम NAME: MR. SATYAM

आयु AGE: 8 months 29 days

लिंग/SEX: M

S/O: VISHNU

पता ADDRESS:

मकान संख्या H.NO:

540, POOJA COLONY

शहर प्रखंड CITY BLOCK

राज्य STATE:

UTTAR PRADESH

मोबाइल MOBILE NO:

7827597831

गली / मुहल्ला STREET/MOH: LONI GHAZIABAD

पिन PIN:

दूरभाष नं. PHONE NO:

7827597831

स्थान Location:

Paediatrics Emergency

BY Brought by Relative

Criticality: Red / Yellow / Green

Triage: Responsive/
Unresponsive

HR

/min

BP

mmHg RR

/min

spO2

%

Shifted to Paeds/ Main/ New Emergency

(↓ pool onw)

Presenting Complaints

(Retnab 68 home)
Sent from Day care for
Blood transfusion
Blood is collected from
day care

Primary Assessment (ABCDE): Assessment Pentagon

Airway

Open & stable Yes/No
If No.....

Breathing: RR 25/min

Efforts: Normal/Poor/increased

Auscultation:

Air entry:

Normal/poor/Differential

Added sounds:

None/Stridor/Wheeze/Crackles

SpO2 on Room air 98%

Circulation

HR 103/min

CFT 43secs.

BP.....mmHg

Peripheral pulse: Poor/Good

Central pulse: Poor/Good

Skin temp: Warm/cool

Others

Disability

GCS 15/Active/Alert

Pupil size 3mm/min

Pupillary Reactions 2

Motor activity:

Normal &

Symmetrical/Asymmetrical/

Posturing/Flaccidity/Seizure

Blood Sugar.....mg/dl

Exposure:

Temp 36.6

Colour: Normal/pallor/cyanosis

mottled

Any other skin lesions.....

Diagnosis

Transfuse PRBC 60ml over 4 hrs.
↓
w/ BT 128ix 5mg i-v 8 hrs

Dr. ARUNKUMAR M

15/11

Daycare

40 cough :: night, day
no fever, no RD

a/w vomiting

O/E chest clear, conjunctivae (+)
no e/o RD.

Plan

(1) Syrup CETRIZINE (5ml/5mg) 2.5ml H/S x 5 days
X ——— 0

(2) Syrup EMSET (5ml/2mg) 3ml TDS x 3 days
————— 0 ——— 0 ——— 0

(3) T. DEXA (0.5mg) 1 tab BD x 3 days
————— 0 ——— 0

Shruti
En POC

28/9/24

28/9
7.7 > 9940 (70100)
3180

B/L PB - (R) up B - 1 kg more dt.

(L) up E - 1/5m H/D/CL

(14/9 - 15/9/24)

- Afebrile :: 19/9

RK appointment on 30/9/24

RC disc - (L) lobes mass L

- ON enhancement - Not present.

← Enucleation deferred due to fever

Op - Diaper rash

ESTIMATE CERTIFICATE TO WHOM IT MAY CONCERN

This is to certify that Shri/Ms. Satyam Verma Age 14 months Gender M
S/o, ~~D/o~~, ~~W/o~~ Vishnu Verma is getting treatment under Ophthalmology Dep
vide registration no. UHID No. 10 7475311

is suffering from Retinoblastoma

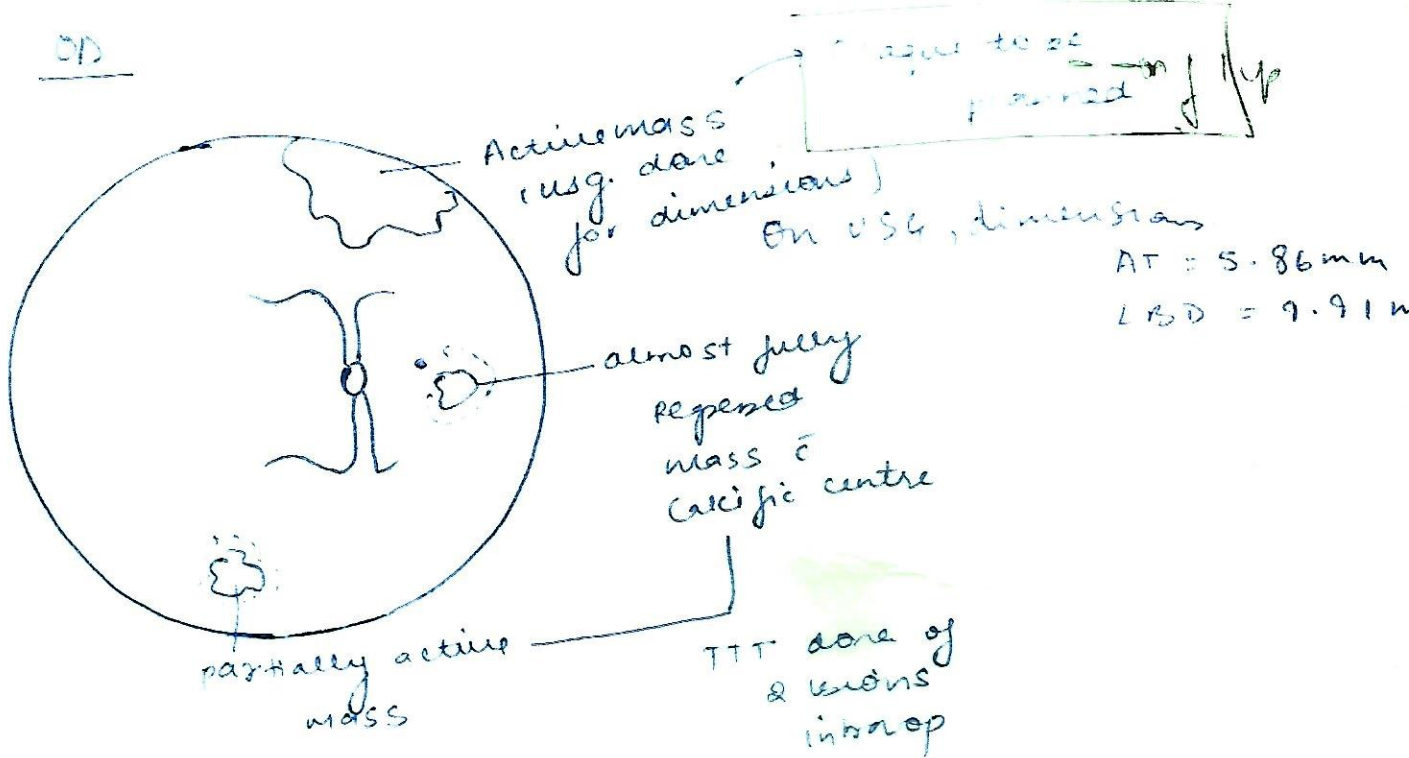
He/she has been advised for surgical items for IAC procedure of 1 cycles for regimen and the
approximate cost of the total treatment is Rs. one lakh one thousand four hundred

(in words) Rupees thirty eight rupees

Item-wise break-up of expenditure of the estimate (if applicable) is as below.

1. INJECTION OMNIPACONE/LOMERON 300mg/50ml	1000RS
2. THREE WAY CONNECTOR(BD)-1	268RS
3. SHORT CONNECTING TUBES WITH 3 WAY-2	120RS
4. LONG CONNECTING TUBES WITH 3 WAY-2	308RS
5. LUER LOCK SYRINGES 10ml/0.1ml-1	43RS
6. MEDICUT 18G/PUNCTURE NEEDLE 18G/21G-1	315RS
7. EXCHANGE GUIDEWIRE(TERMO) 150cm, 32 ANGLED-1	2226RS
8. DOUBLE LARGE BORE Y-CONNECTOR(MERIT)-1	1250RS
9. FEMORAL SHEATH(ARROW) 5F X 7.5cm-1	1224RS
10. ENVOY 5F-1	12584RS
11. MARATHON-1/HEADWAY 21	52700RS
12. HYBRID/MIRAGE-1	26900RS
13. INJECTION MELPHALON 50mg/10ml	2,500RS
14. INJECTION TOPOTECAN 2.5mg/2.5ml	4,000RS
15. INJECTION CARBOPLATIN 150mg/15ml	1,000RS

OD



26/3/25

RIS Plaque Dosimetry

→ Sheath thickness 0.8mm

→ Notched plaque

USG

AT 5.86
LBD 9.91

Dosimetry → Mon / Thu

IRCH

9:00 AM

Room 39

Dr. Sureshwar Saini

Signature

L2. (Secd Mon - 0 37 10x 1w -) 4x 10x 1w -)

3 -> 2 -> 1 -> Stop

118 { Secd defunct change 67 to

Flupl next week
on Monday 11:00

Signature

5/4/25

do (R) up multifocal B. LB

(L) up E LB

received 6# HDTU, last received in Nov '24

underwent enucleation on 18/3/2025 (L) eye

HPE → no HRF
 also poorly differentiated RB + calcification
 silene, iris, vitreous body, choroid, ON.
 including its cut end free of tumor

EUP (R) eye → active mass → plaque therapy
 almost fully regressed
 mass + calcific nodule
 partially active mass

+++ done on the 2 lens

child is planned for plaque therapy
 ↓
 has been told to meet Dr. Sarin on
 Monday.
 2 Rb in optical → on week.

4D/w Prof. R. Sethi M.A.M.

↓
 I/O B/L and
 multifocal disease,
 possibility of RB1
 gene mutation. To
 do RB1 gene mutation
 In such a case may be
 better to avoid RT and
 consider for IAC

Adv Adv
 (NIV) in OPD on 12/4/2025.

Plan → RB1 gene
 mutation.
 ↓
optical review

funer
 SA

To
~~Dr. Sarin~~
 Please
 keep.

Dr. Shreshitha Kaushik
 Senior Resident
 Ophthalmology
 Department of Ophthalmology
 All India Institute of Medical Sciences
 New Delhi-110029

child is a clo up B unilateral RB, & active
 mass persisting in R eye → planned for plaque.
 L eye enucleated, no high risk features. Possibility
 of genetic basis present. Should IAC / or chemotherapy
 be considered over plaque brachytherapy.
 kindly opine. we have planned RBL gene mutation

Thank You,

Signature
 Dr. Shreshtha Kaushik
 Senior Resident
 DM, Pediatric Oncology
 Department of Pediatrics
 AIIMS New Delhi-110029

S	4	25
---	---	----

To

Carikids,

kindly help to do RBL gene mutation
 for the patient.

Thank You,

Signature
 Dr. Shreshtha Kaushik
 Senior Resident
 DM, Pediatric Oncology
 Department of Pediatrics
 AIIMS New Delhi-110029

RBL gene
 mutation

5/1/24

Dr. RACHIN SETHI
 Senior Resident / Professor
 Department of Pediatrics
 AIIMS New Delhi-110029

ICS please
 mail
 Alex

19/04/25


No fresh complaints.

Planned for single drug IAC (Melphalan) CRT

A&V

____ RPE followup

____ N/V → 2/04/25 Doc @ 2pm



 Dr. Ruksana Siddique, FR
DM Resident
Pediatric Oncology
AIIMS, New Delhi